

Anatomical insertion variation of Peroneus tertius

Authors: Bansal A, MBBS student, AIIMS Guwahati; Bokan R, Assistant Professor, Department of Anatomy, AIIMS Guwahati; Praveen K, Associate Professor, Department of Anatomy, AIIMS Guwahati; Deka R, Professor & Head of the Department, Department of Anatomy, AIIMS Guwahati

ABSTRACT

Peroneus tertius, an unipennate muscle, exhibits variations in insertion, as observed in a female cadaver study. Additional slips attaching to extensor digitorum longus were found 16 cm below its origin.

Keywords: Anatomical variation; Tendon insertion; Dorsum of foot; Surgical anatomy

INTRODUCTION

The peroneus (fibularis) tertius is a variably present muscle of the anterior compartment, contributing—albeit weakly—to ankle dorsiflexion and eversion at the talocrural and subtalar joints. It typically arises from the distal fibula, interosseous membrane, and anterior intermuscular septum and inserts on the dorsomedial base of the fifth metatarsal via a tendon; it may be absent or confluent with the extensor digitorum longus (EDL) (1). Olewnik’s classification describes several insertion patterns, with type II most common (~84.8%), while the type IV pattern—a split insertion to the base and shaft of the fifth metatarsal—is uncommon (~1.5%) (2). Occasional tendinous connections with EDL have also

been reported (~10.6%) (2). These variants likely reflect developmental deviations in myotendinous formation and carry practical implications for physiotherapists and orthopaedic surgeons during tendoplasty and lateral foot procedures. We present a type IV variant with split insertion consistent with this scheme.

Case report: During the course of educational dissection of anterior compartment of leg and foot of a aged female cadaver on the left foot the insertion of the peroneus tertius muscle is observed and seen that there is a variation in the insertion of peroneus tertius. It is usually inserted on the base of fifth metatarsal but in this case the insertion is appreciable on the shaft of 5th metatarsal and also on base of 5th metatarsal. And one more case report you can see that there is joining tendon between extensor digitorum longus and peroneus tertius

FIGURES AND IMAGES

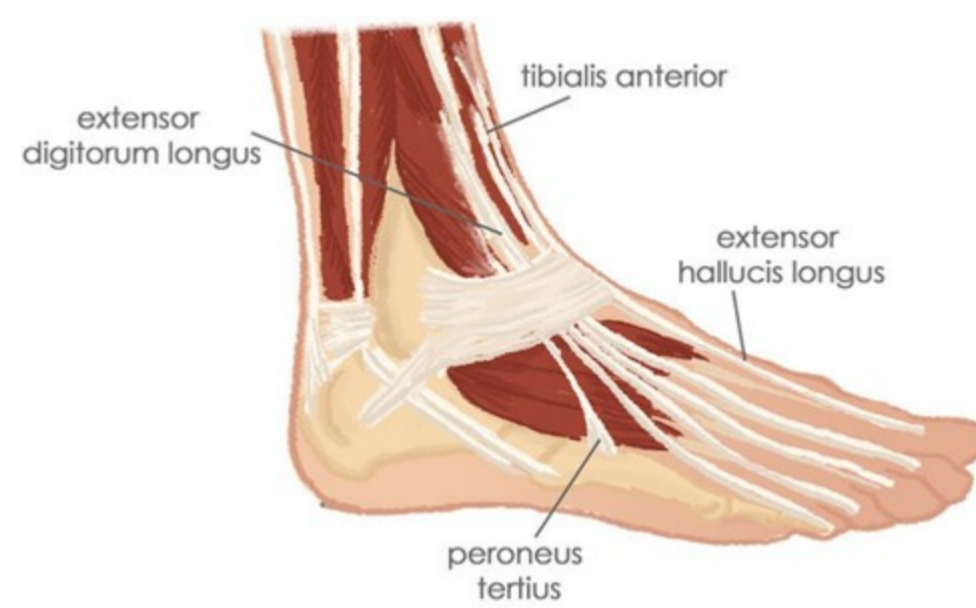


Figure 1. Anterior ankle-foot schematic showing the extensor tendons crossing the talocrural joint. Tibialis anterior, extensor hallucis longus, and extensor digitorum longus (EDL) are shown medially to laterally; the peroneus (fibularis) tertius (PT) runs most laterally toward the dorsolateral foot, illustrating its typical course to the fifth metatarsal

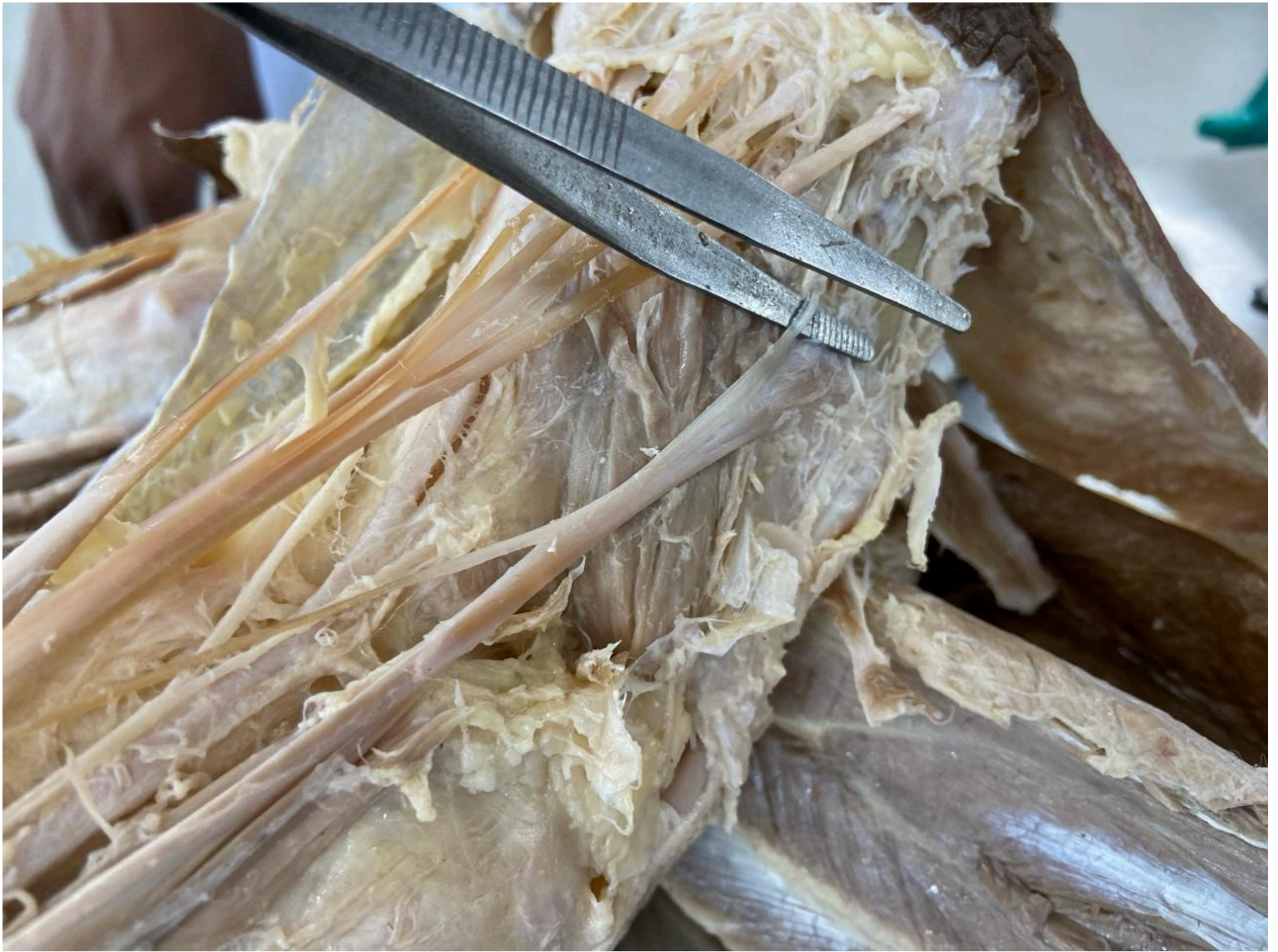

Figure 2. Cadaveric dissection (distal leg/ankle) highlighting a slender anomalous tendinous slip between EDL and PT (held in forceps). This communicating band links the distal EDL to the PT tendon, an accessory connection relevant during tendon transfers and anterior ankle approaches.

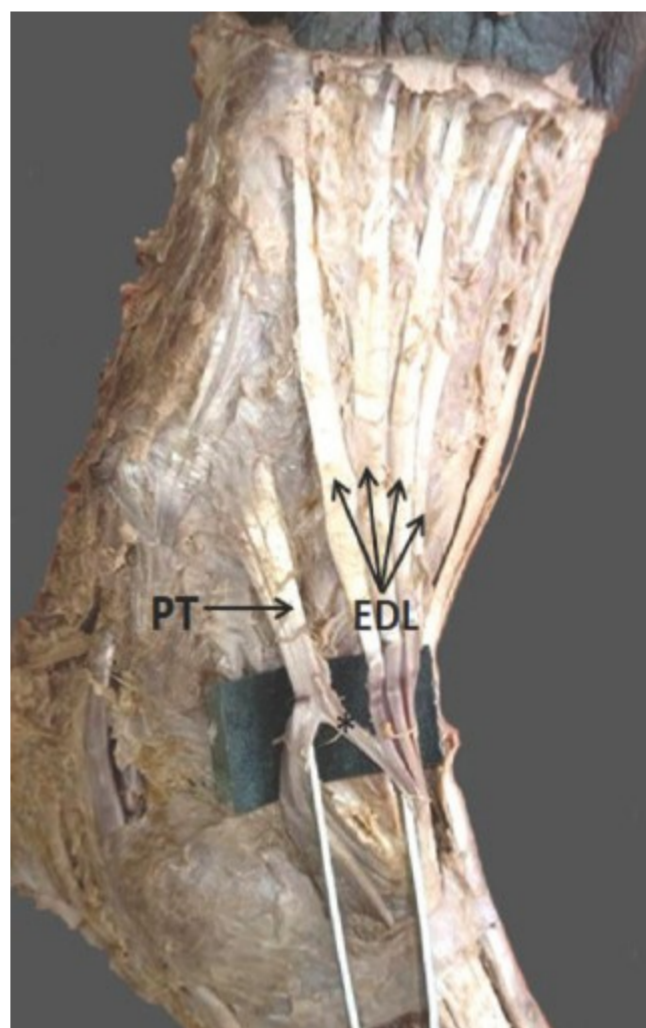


Figure 3. Proximal view of the distal leg with the extensor retinaculum reflected. Multiple EDL slips (arrows) are seen centrally; the PT tendon (PT →) lies lateral to EDL, demonstrating the topographic relationship of PT to the extensor compartment before its distal divergence.

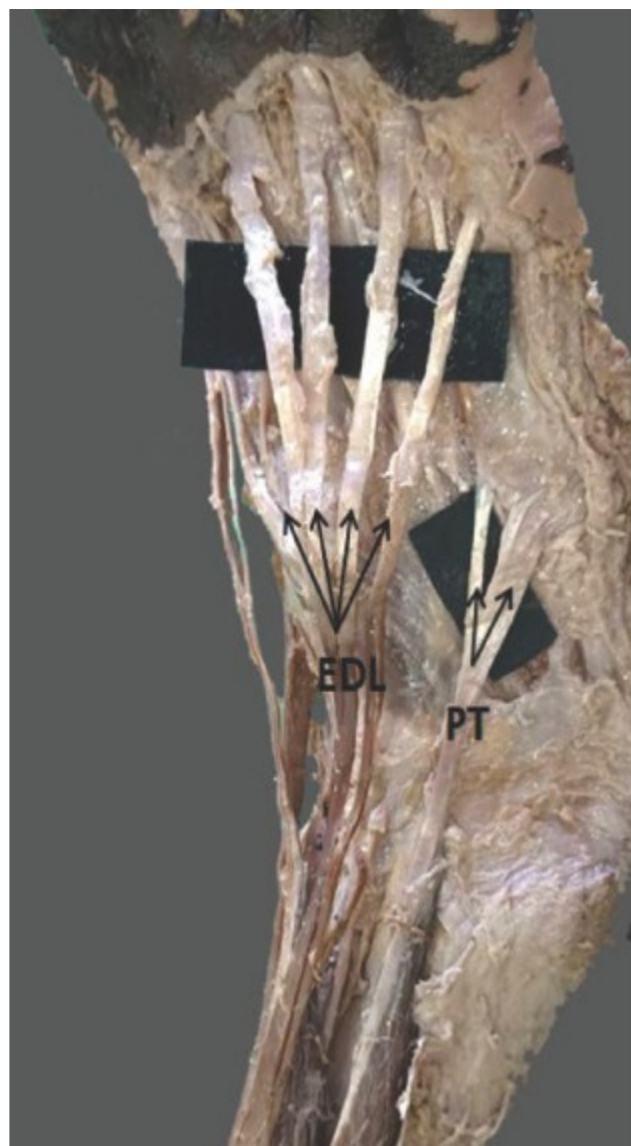


Figure 4. Dorsum-of-foot dissection showing the terminal course of PT (PT label). The tendon divides distally into two terminal slips—one to the base and another to the shaft of the fifth metatarsal—consistent with Olewnik type IV split insertion.

TABLES

Olewnik classification of peroneus (fibularis) tertius (PT) distal insertion variants. Types I–VI categorize PT by its terminal tendon attachment on the lateral forefoot. Our specimen corresponds to Type IV, showing a split insertion to the base and shaft of the fifth metatarsal—anatomy relevant to tendoplasty planning and dorsolateral foot surgery.

Type	Definition
Type I	Single insertion into the shaft of 5th metatarsal
Type II	Single insertion into the base of the 5th metatarsal
Type III	Wide insertion into the base of 4th and 5th metatarsal
Type IV	Split insertion, one of which inserted into the base and other into shaft of 5th metatarsal
Type V	Split insertion, one to base of 4th and other to the 5th metatarsal
Type VI	Communicating with peroneus brevis (PB) or Extensor digitorum longus (EDL).

Olewnik classification of peroneus (fibularis) tertius (PT) distal insertion variants. Types I–VI categorize PT by its terminal tendon attachment on the lateral forefoot. Our specimen corresponds to Type IV, showing a split insertion to the base and shaft of the fifth metatarsal—anatomy relevant to tendoplasty planning and dorsolateral foot surgery.

DISCUSSION

Fibularis Tertius Syndrome is a condition characterized by catching, clicking, locking or popping of peroneus tertius tendon over ankle during walking. It is a rare condition of anterolateral ankle pain or rear foot pain. This could be secondary to impingement and constriction of PT in the extensor retinaculum.

CONCLUSION

Our case report highlights unique variations in peroneus tertius muscle insertion, including a split insertion onto the 5th metatarsal classified as type IV. Understanding embryological origins elucidates such variations, crucial for surgical planning. Anomalies like tendinous slips

between extensor digitorum longus and PT underscore anatomical complexity. Accurate anatomical knowledge is essential for clinical practice and education.

REFERENCES

1. Olewnik Ł, et al. Fibularis tertius: anatomical study and review of the literature. Clin Anat. 2019.

Wiley Online Library

2. Afroze MKH, et al. Morphological variations of

August 20p, 2e0ro25neus tertius: a cadaveric study with anatomical and

clinical consideration. 2020. PubMed Central

3. Palomo-López P, et al. Fibularis tertius muscle in women and men: a surface anatomical study. 2019.

PubMed Central

4. Yammine K. The fibularis (peroneus) tertius muscle in humans: an evidence-based review. 2017.

PubMed Central

5. Bauer SA, et al. Peroneus tertius revisited: morphological variability of the fibularis tertius tendon. 2023.

ScienceDirect

6. Subramanian S, et al. Anatomical variations of peroneus tertius and its clinical implications: case report with systematic literature review. 2023.

PubMed

7. Ercikti N, et al. Insertional characteristics of the peroneus tertius tendon. J Foot Ankle Surg. 2016.

ScienceDirect

8. Abhinitha P, et al. Anomalous pattern of tendinous slips

Variant Insertion of the Peroneus Tertius

of peroneus tertius and extensor digitorum longus: a

clinically important variation. Gulhane Med J. 2014. gulhanemedj.org

9. Tidball JG, Lin C. The development of the myotendinous junction: a review. 2013.

PubMed Central

10. Iceman K, et al. Peroneus tertius syndrome: a rare cause of anterolateral ankle pain. J Foot Ankle Surg. 2020. jfas.org