

## Supernumerary Head of Biceps Brachii: A Case Report

**Authors:** Singh P, MBBS Student, AIIMS Guwahati, Raju B, Associate Professor, Department of Anatomy, AIIMS Guwahati, Dr. Praveen K, Assistant Professor, Department of Anatomy, AIIMS Guwahati

### ABSTRACT

The biceps brachii is a muscle of the anterior compartment of the arm, typically composed of two heads that fuse into a single muscle belly. During routine cadaveric dissection, we observed a unilateral supernumerary (third) head originating from the anteromedial surface of the humerus. Recognition of such variations is important for clinicians, radiologists, and surgeons due to their potential clinical implications.

*Keywords:* anatomy, anterior compartment, scapula

### INTRODUCTION

The biceps brachii is a prominent muscle of the anterior compartment of the arm, primarily responsible for flexion of the elbow and supination of the forearm. It conventionally has two heads: the short head originates from the lateral side of the tip of the coracoid process of the scapula, while the long head arises from the supraglenoid tubercle of the scapula. Both heads fuse to insert into the radial tuberosity. The muscle is innervated by the musculocutaneous nerve.

Embryologically, the long head arises from the glenoid labrum, and evolutionarily, homologous structures are observed in reptiles and birds. Anatomical variations such as the presence of

additional heads have been reported and can have clinical relevance.

### Case Report

During routine dissection of a male cadaver in the Department of Anatomy, AIIMS Guwahati, an anatomical variation was identified in the right arm. A third head of the biceps brachii was observed, originating from the anteromedial surface of the humerus, just below the origin of the brachialis muscle.

The third head measured 11.2 cm in length, with an approximate width of 2 cm at the insertion point. It merged with the main muscle belly and was innervated by a branch of the musculocutaneous nerve. The head was visible upon lifting the long head with forceps. No similar anomaly was found on the contralateral side.

### FIGURES AND IMAGES

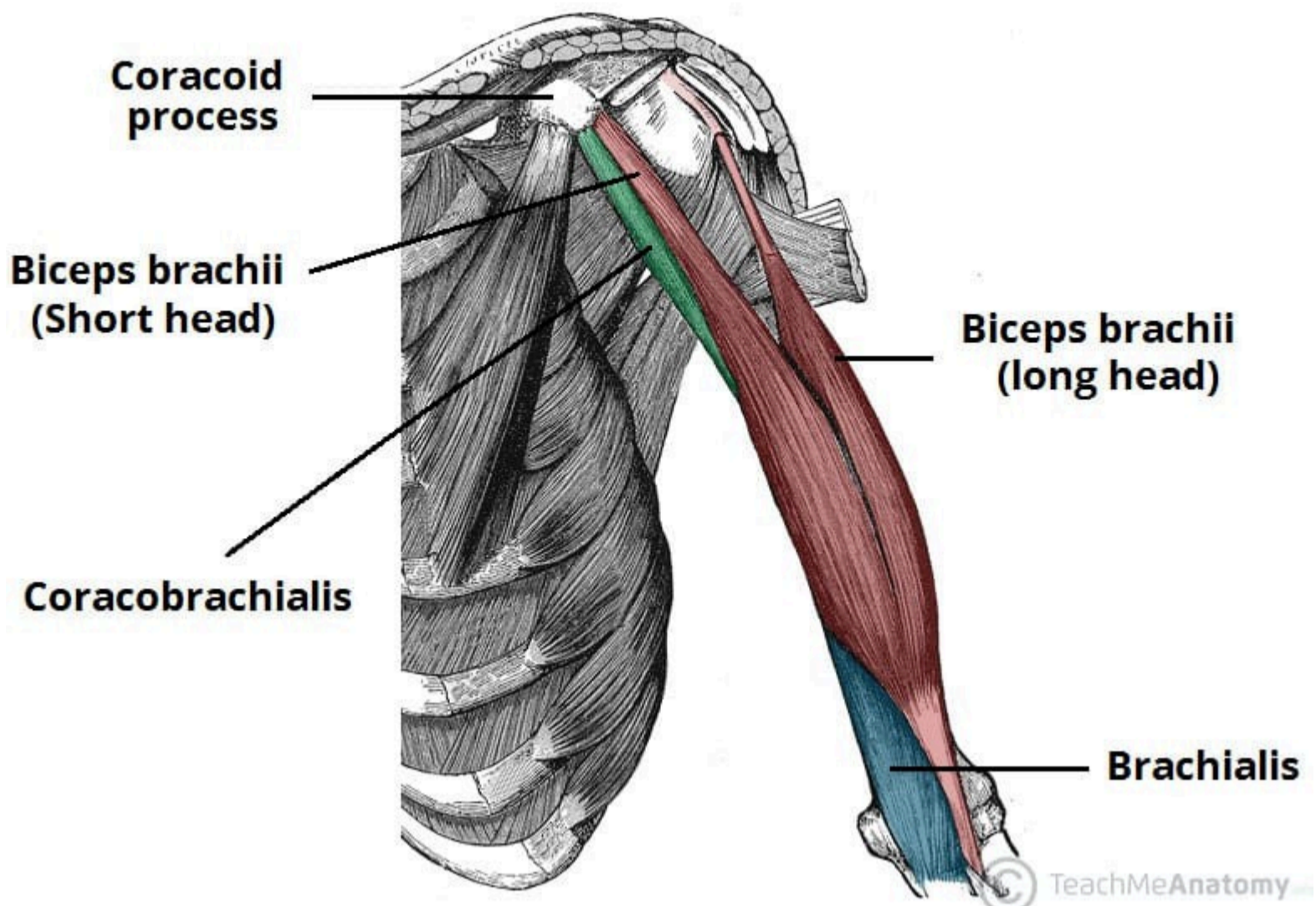


Fig 1- Origin, insertions and Relations of Biceps Brachii muscle shown in reddish brown colour

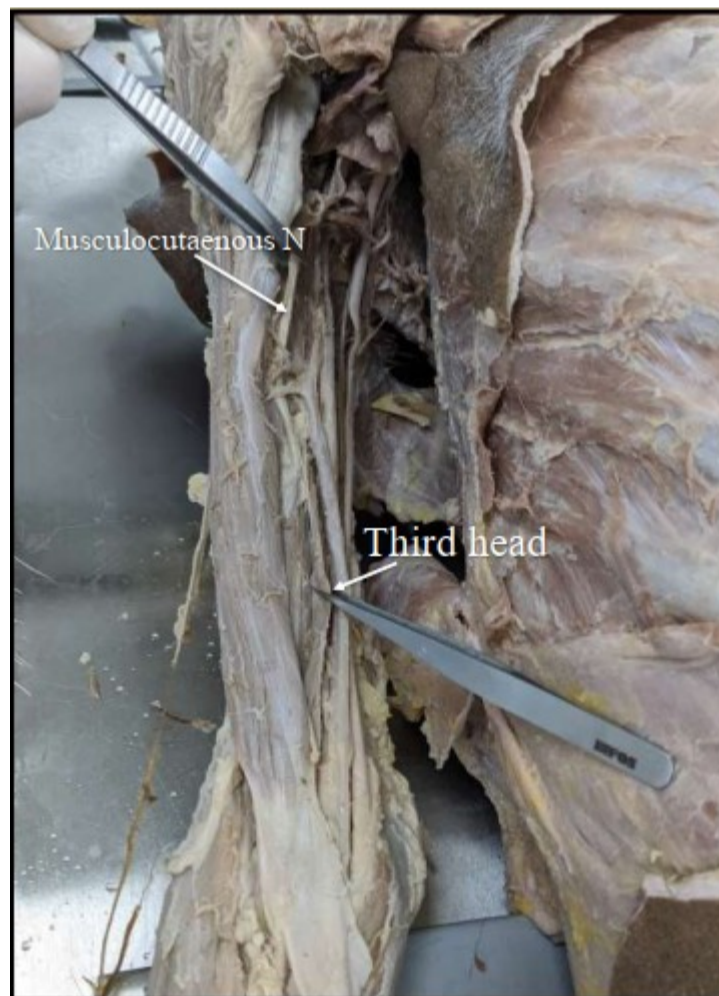


Fig 2- Showing third head supplied by Musculocutaneous Nerve

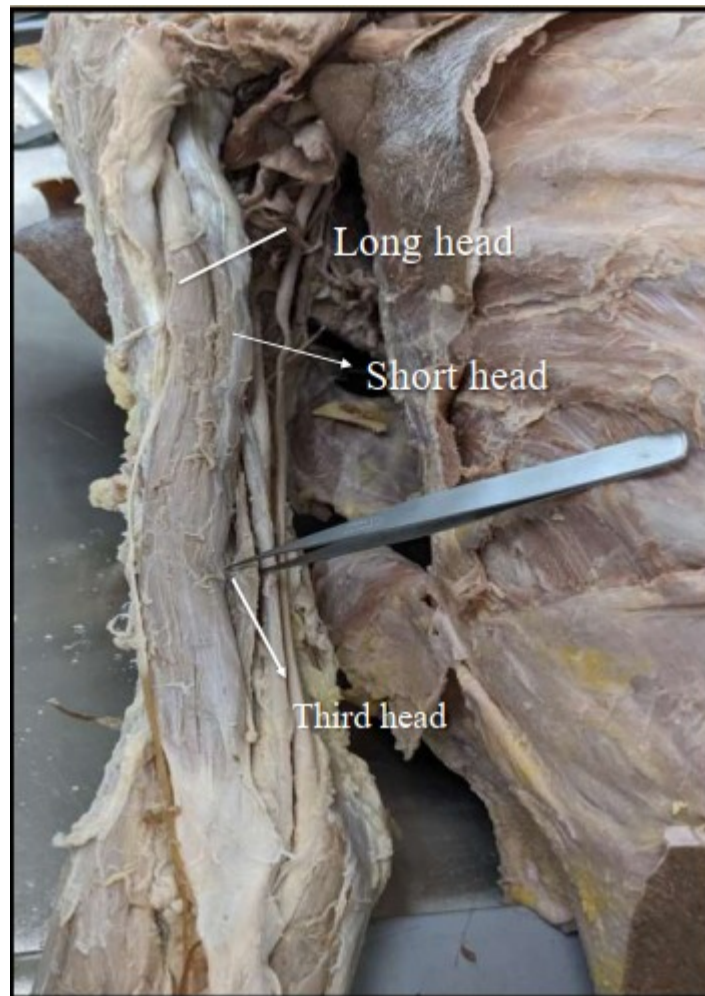


Fig 3- Relations of the third head with other 2 heads of Biceps brachii



Fig 4- Measurement of the third head of Biceps brachii with the help of a ruler.

## DISCUSSION

Manjatika et al. (2024) reported a 20.2% prevalence of a third head of the biceps brachii, with a higher occurrence in males (22.2%) than females (18.2%). Around half of these cases were bilateral. Most (92%) of the accessory heads were flat, thin, and

straight. The anteromedial humerus was the most common site of origin.

Supernumerary heads may confuse radiologists as possible soft tissue tumors and could cause neurovascular

compression, particularly of the median nerve or brachial artery, leading to sensory and motor deficits or ischemia.

In surgical contexts, these variations may influence outcomes in:

- Humeral fracture management
- Reconstructive and flap surgery
- Nerve decompression procedures

## CONCLUSION

The presence of a third head in the biceps brachii muscle represents a noteworthy anatomical variation with potential clinical relevance. Surgeons, radiologists, and clinicians must remain aware of such variations to avoid diagnostic confusion or intraoperative complications. Such knowledge is essential for improving outcomes in orthopedic and reconstructive interventions.

## REFERENCES

1. Szewczyk B, Sanudo JR, Podgórski M, et al. A Proposal for a New Classification of the Supernumerary Heads of the Biceps Brachii Muscle. *Biomed Res Int.* 2022;2022:1510363. doi:10.1155/2022/1510363
2. Manjatika AT, Davimes JG, Mazenganya P. The third head of the biceps brachii muscle exhibiting variable shape presentation: Prevalence, variability and clinical considerations. *Transl Res Anat.* 2024;34:100282.
3. de la Cuadra-Blanco C, et al. Development of the human biceps brachii tendon and coracoglenoid ligament (7th–12th week of development). *Cells Tissues Organs.* 2017;203(6):365–373.
4. Drake RL, Vogl AW, Mitchell AWM. *Gray's Anatomy for Students.* 4th ed. Philadelphia: Elsevier; 2019.
5. Romanes GJ. *Cunningham's Manual of Practical Anatomy.* Vol. 3: Head, Neck and Brain. 15th ed. Oxford: Oxford University Press; 2017.